

## Accidental Pharmacological Mydriasis; Hazard To Anaesthetist : A Case Report

Joshi Anumeha, JhaSharda, Ruhela Ankit

---

### **Abstract:**

*Atropine is an antimuscarinic (a type of anticholinergic) that works by inhibiting the parasympathetic nervous system.<sup>1</sup> It is on the World Health Organisation's list of essential Medicines, the safest and most effective medicines needed in health system.<sup>2</sup> Topical atropine is used as a cycloplegic to temporarily paralyse the accommodation reflex and as mydriatic to dilate the pupils.<sup>3</sup>*

*Anisocoria is a condition in which the pupil of one eye differs in size from the pupil of the other. (reference not known) A large unresponsive pupil may represent an ominous sign of potentially disastrous intracranial disease, but it may also result from trivial application, inadvertent or intentional of a mydriatic drug to the eye.<sup>4</sup>*

*Our case report describes a case of accidental pharmacological mydriasis in a 34 year old female anaesthetist who presented with right sided mydriasis. Her right pupil was unresponsive to light and accommodation. This resulted due to the accidental spillage of IV atropine into her eye while she was forcefully injecting the drug through the IV cannula of a patient in operation theatre. She was incapacitated for the whole day and her symptoms improved the next morning. This unique case poses accidental pharmacological mydriasis as a serious occupational hazard to anaesthetists.*

**Keywords:** atropine, accidental pharmacological mydriasis, occupational hazard

---

Date of Submission: 18-06-2020

Date of Acceptance: 04-07-2020

---

### **I. Introduction:**

Atropine acts as a competitive antagonist of acetylcholine at muscarinic receptors.<sup>5</sup> In cardiac uses, it works as a non selective muscarinic acetylcholine antagonist increasing firing of SA and conduction through the atrioventricular node of the heart, opposes the actions of the vagus nerve, blocks acetylcholine receptor sites and decreases bronchial secretions.

In the eye, atropine induces mydriasis by blocking contraction of the circular pupillary sphincter muscle which is normally stimulated by acetylcholine release, thereby allowing radial iris dilator muscle to contract and dilate the pupil.<sup>3</sup>

Medication error is a major cause of morbidity and mortality in medical profession and anaesthesia and critical care are no exception to it. Man, medicine and modus operandi are the main contributory factors to it.<sup>6</sup>

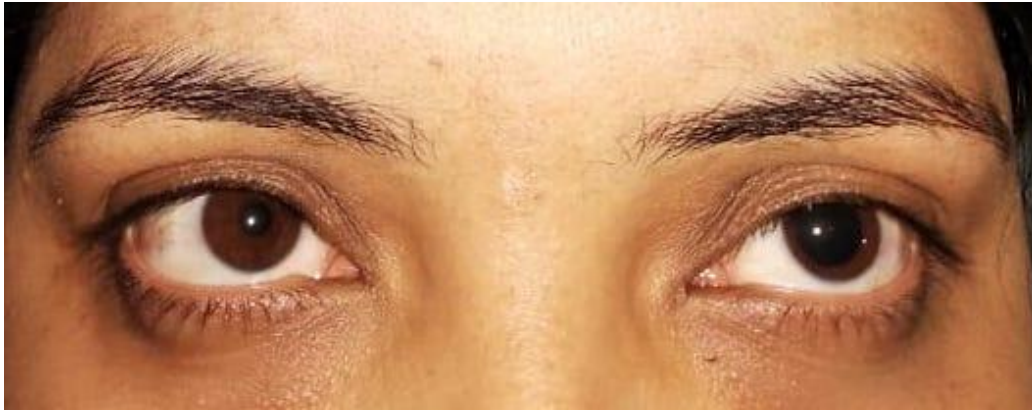Historically, the greatest occupational hazard encountered by an anaesthetist was the threat of a fire or explosion while using a potentially explosive anaesthetic agent. Replacement with non explosive agents has rendered this hazard virtually obsolete in modern anaesthesia.<sup>7</sup>

Although for anaesthetists, the most likely source of an occupational exposure is self inoculation from a needle during the insertion and suturing of intravascular catheters, the injection of intradermal anaesthesia or resheathing of used needles<sup>8</sup> but our case report highlights the hazard during drug injection in the form of accidental pharmacological mydriasis.

### **Case report:**

A 34 year old female anaesthetist presented with history of progressive right sided blurring of vision and headache in operation theatre. She was myopic with visual acuity of 6/60 in both eyes. There was no accompanying ptosis and range of eye movements were full.

On examination, anisocoria was detected where right pupil was found to be in fixed mydriasis and was unreactive to light and accommodation.



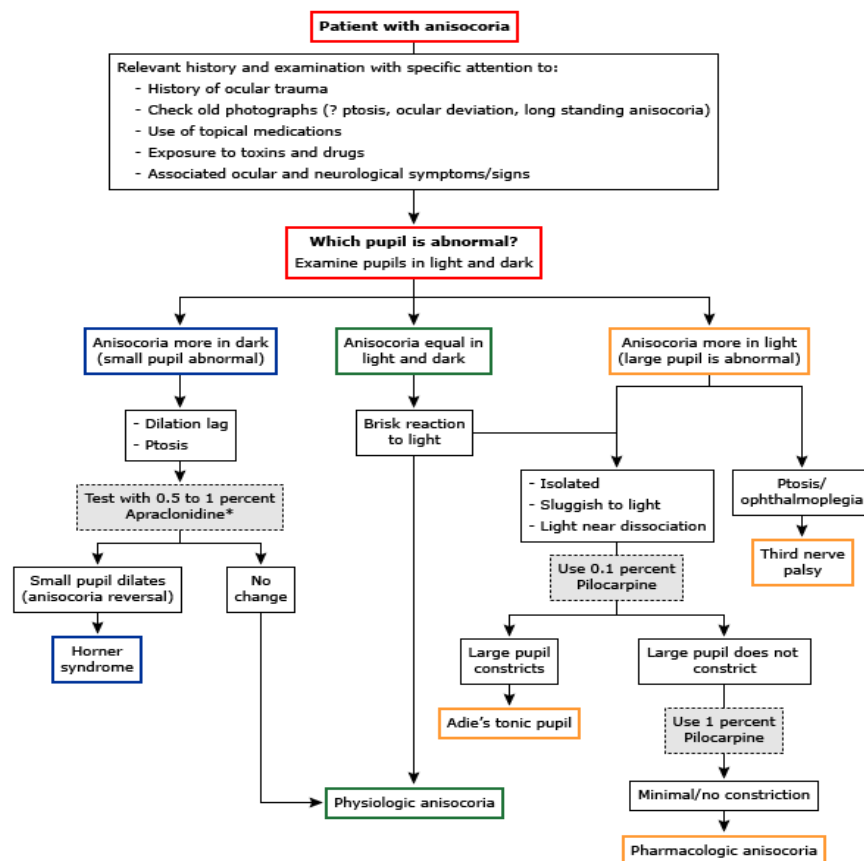
Her vitals were immediately recorded and were found to be within normal limits. Her only complaint was headache. There was no history of pain in eyes, nausea, fever, trauma, hypertension or stiffness in the neck. Initially, she strongly denied using any topical ocular medications but later on, she recalled that an hour ago while she was injecting IV atropine through the IV cannula of a patient in operation theatre, there was accidental spillage of drug and few drops were accidentally instilled into her right eye. She was incapacitated to the extent that she was unable to perform her hospital duty and needed someone to accompany her on her way back home. Her signs and symptoms improved over the next day.

## II. Discussion:

Anisocoria or unequal pupil sizes is a common condition. Approximately 20% of the normal population have physiological anisocoria.<sup>9</sup> However, pathological anisocoria indicated disease of the iris, parasympathetic pathway or sympathetic pathway.

Flowchart explaining approach to a patient with anisocoria.<sup>10,11</sup>

Flowchart explaining the approach to a patient with anisocoria



Differential diagnosis of normally reactive pupils :

Physiological anisocoria

Horner's syndrome

Differential diagnosis of poorly or non reactive pupils :

Iris sphincter damage(traumatic mydriasis)

Pharmacological blockade

Tonic pupil

Cranial nerve III palsy

Pharmacological anisocoria should be taken in the possible diagnosis especially in the setting of an operation theatre.

Moreover, the situation in our case raises the question of another occupational hazard to anaesthetist inflicted during drug injection apart from the needle stick injury.

This hazard can be prevented by cautious use of IV medications and raises the question of need of a protective gear like goggles in operation theatres.

### **III. Conclusion:**

Accidental pharmacological mydriasis needs to be addressed as a serious health hazard to the anaesthetist. In our case report, the anaesthetist had to suffer from blurring of vision and headache which incapacitated her to the extent that she could not perform her duty in the hospital and could not go back home without any assistance. This further intensifies the need of using protective gear like goggles beyond their use in sero positive cases.

### **References:**

- [1]. "Atropine"( <https://www.drugs.com/monograph/atropine.html>). The American Society of Health System Pharmacists. Archived(<https://web.archive.org/web/20150712191611/http://www.drugs.com/monograph/atropine.html>) from the original on 2015-07-12. Retrieved Aug 13,2015.
- [2]. World Health Organization(2019). World Health Organization model list of essential medicines:21<sup>st</sup> list 2019. Geneva: World Health Organization. Hdl:10665/325771(<https://hdl.handle.net/10665%2F325771>) WHO/MVP/EMP/IAU/2019.06. License: CC BY-NC-SA 3.0 IGO.
- [3]. Wikipedia
- [4]. Ulf Havelius, Peter Asman(2003):Accidental mydriasis from exposure to Angel's trumpet(Datura suaveolens). Acta Ophthalmologica Scandinavica Volume 80,issue 3.
- [5]. Bishop AG, Tallon JM . Anticholinergic visual hallucination from atropine eye drops. CJEM. 1999;1: 115-116(PubMed) (Google Scholar).
- [6]. Kothari D, Gupta S, Sharma C, Kothari S: Medication error in anaesthesia and critical care : A cause for concern. Indian J Anaesth 2010;54:187-92.
- [7]. Ian Thomas: Occupational Hazards of Anaesthesia. British Journal of Anaesthesia 2006;6/5/182-187.
- [8]. Greene ES, Berry AJ, Jagger J etal. Multicenter study of contaminated percutaneous injuries in anaesthesia personnel, Anaesthesiology, 1998, vol 89:1362-1372.
- [9]. Lam BL, Thompson HS, Corbett JJ. The prevalence of simple anisocoria. Am J Ophthalmol 1987;104(1):69-73.
- [10]. WanTsu Wndy Chang: Evaluation of anisocoria. Department of Emergency Medicine 2014.
- [11]. Kedar S, Biousse V, Newman NJ. Approach to the patient with anisocoria. In: UpToDate, Brazis, PW (Ed), UpToDate, Waltham, MA, 2014. (Accessed on November 12, 2014.)

Joshi Anumeha. "Accidental pharmacological mydriasis; hazard to anaesthetist : a case report." *IOSR Journal of Research & Method in Education (IOSR-JRME)*, 10(4), (2020): pp. 43-45.